

Name: _____

Anatomy of the Heart

PULMONARY ARTERY

PULMONARY VALVE

MITRAL VALVE

RIGHT ATRIUM

LEFT ATRIUM

TRICUSPID

VENA CAVA

VENTRICLE

AORTIC

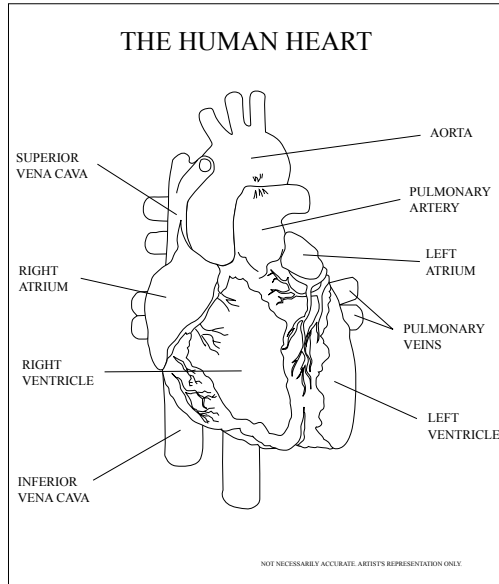
AORTA

HEART

RIGHT

VEINS

LEFT



E M J M P C I P W B Z G J S K G A S I S X K B W
C V E N T R I C L E D E R Y M G I C R V M Q D J
B A X G K A Z I N W V N O P R B H F Z S V H V H
J Q R X Q Q E W F L S L B F B W P H E A R T B L
R B R L T H A V A T F H H T M V P P E P T C D Y
S P G I Q S M V L E V Z T R L A R Y A S V D X H
P C O M O C L U N A W F C G O N K X A E I I M D
U J L M O A C C I J V Q K R F O R U M P X V E Q
K U Q O R C C H T R M Y T X K W G H S P B D M C
L Q J T S A N N B Q T I R M E Y M U V D I W A O
L P I Z L F H R U X C A D A U D C T D O Z N B U
G M G H Q K D A S I A I T M N I W T Y J G A H K
T H G I R X Q D S N Y Y W H R O R Z E E J Z M G
P J O Q G Z E P Q O I B T T G V M T A L D Z B F
M V R L X F K M P V W E V B Z I Q L A W M Y Y A
K O B U D Q J W G I U N V U V E R I U T E N G R
A V N K B P W S G C T P O H Q N X E T P F O N P
Q X N G Y R E T R A Y R A N O M L U P S V E T J
J W A Z P A V A C A N E V L Y D R T F F D A L V
P H R Q Q Y S W U M C J Y I O W G G F Q A O B E
A P N W L K F W A G I H V S F L X X F E G R C F
R R P O T L U P W M R D G X U R H I P A L T S B
S M K E R V I E C T X N B K G X Y R H Z U A O M
O B O F E G W I W A Y M I E E F O G D M G K N T