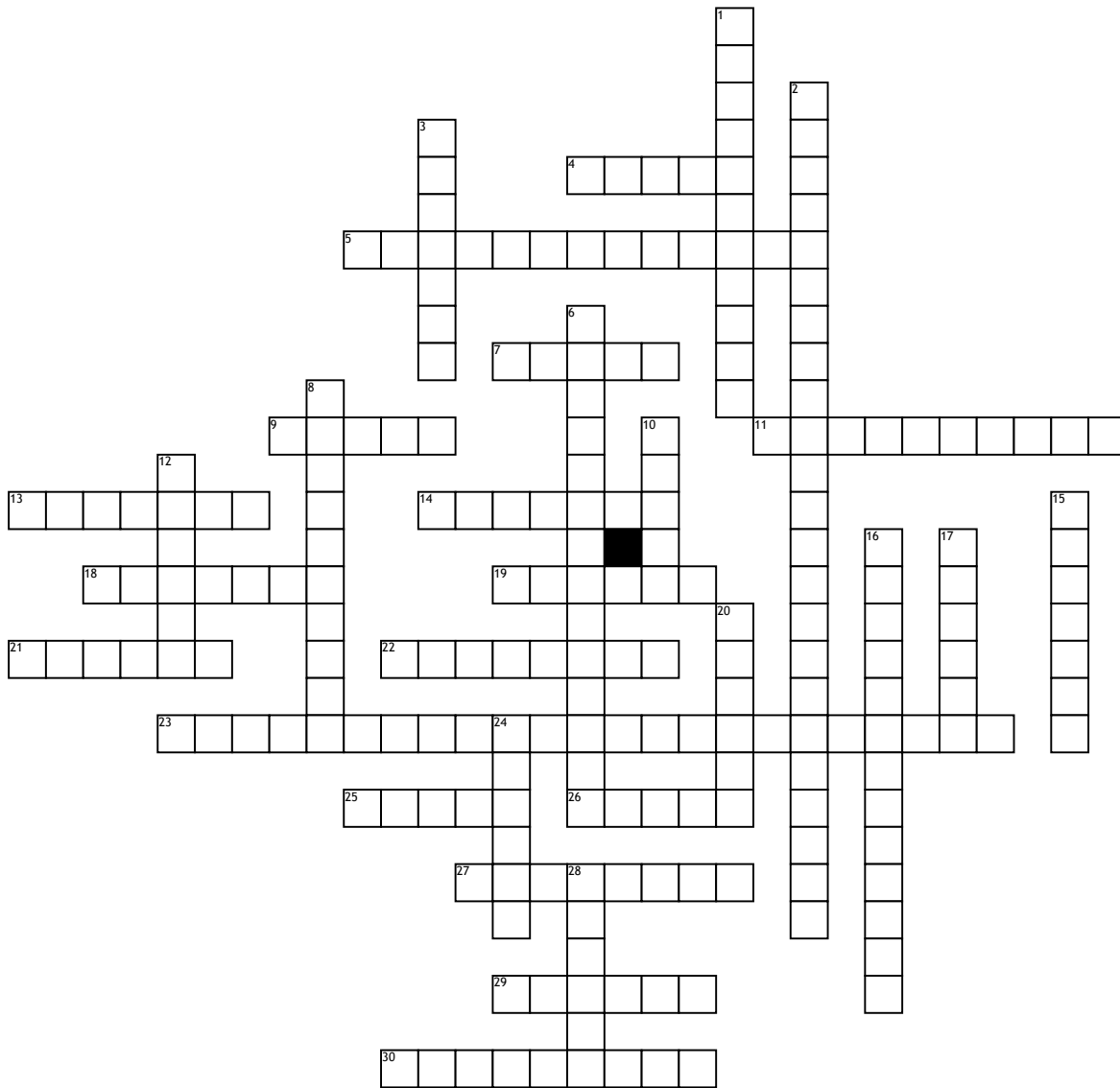


Name: _____

Date: _____

CNHP 2010 Crossword Puzzle



Across

4. a solid mass larger than 1-2 cm
 5. deepest layer of the epidermis, also called the basal layer
 7. a flat, discolored area on the skin larger than 1 cm (e.g., vitiligo)
 9. oily substance secreted by the sebaceous glands
 11. cellular avascular layer covering external and internal surfaces of the body
 13. An acute but mild disease cause by rubella virus, also called German Measles
 14. a linear crack in the skin
 18. tissue
 19. a flat, discolored spot on the skin up to 1 cm across (e.g., a freckle)
 21. an area of pathologically altered tissue; types of lesions are primary, secondary, vascular, and purpuric

Down

22. red
 23. sexually transmitted, ulcer-like lesions of the genital and anorectal skin and mucosa; after initial infection, the virus lies dormant in the nerve cell root and may recur at times of stress
 25. a blister larger than 0.5 cm (e.g., a second-degree burn) (bulla = bubble)
 26. fungus
 27. skin
 29. a solid mass on the skin up to 0.5 cm in diameter (e.g., a nevus [mole])
 30. thickened areas of epidermis

6. the outer layer of the epidermis, made up of several layers of flat keratinized (hard, proteinaceous) cells
 8. cell in the stratum basale that gives color to the skin
 10. an area of localized skin edema (swelling) (e.g., a hive)
 12. formation
 15. nail
 16. a small, round, bright red blood vessel tumor on the skin, seen mostly in people over age 30
 17. a solid mass greater than 1 cm that extends deeper into the epidermis
 20. sweat
 24. a solid mass greater than 1 cm in diameter and limited to the surface of the skin
 28. fat