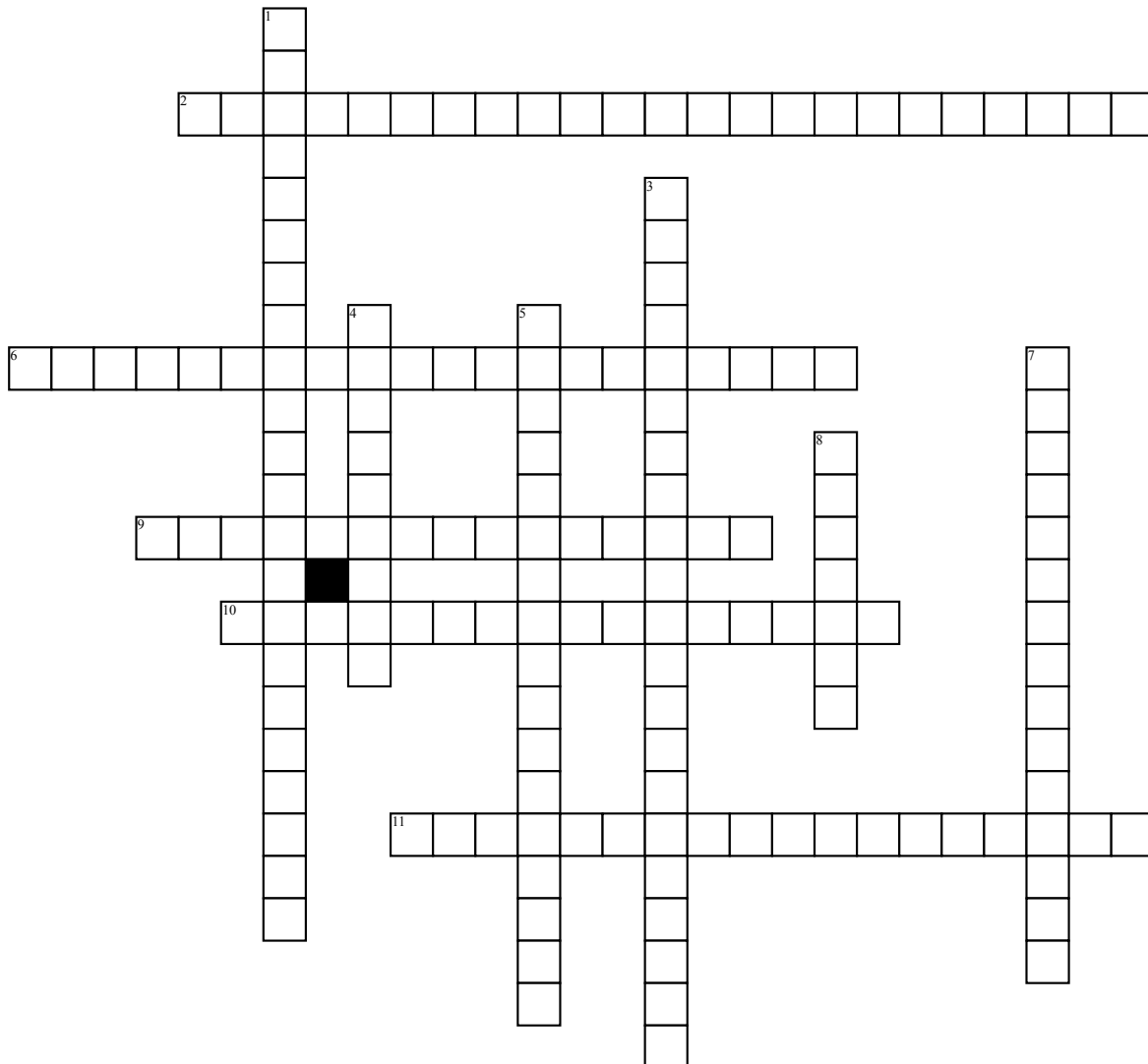


Name: _____

Chaper 19



Across

- 2. Dorsiflexes and inverts the foot, extends the toes
- 6. lower two-thirds of the fibula
- 9. proximal two-thirds of the lateral surface of the fibula
- 10. Dorsiflexes and inverts the foot
- 11. contains the fibularis longus and brevis, the fibularis tertius muscle, and the superficial branch of the potential nerve

Down

- 1. Dorsiflexes and inverts the foot, extends the great toe
- 3. posterior surface of the tibia
- 4. Flexes the leg, plantar flexes the foot
- 5. posterior surface of the interosseous membrane, the tibia, and the fibula
- 7. Distal two-thirds of the fibula
- 8. prevents abduction and eversion of the subtalar joint