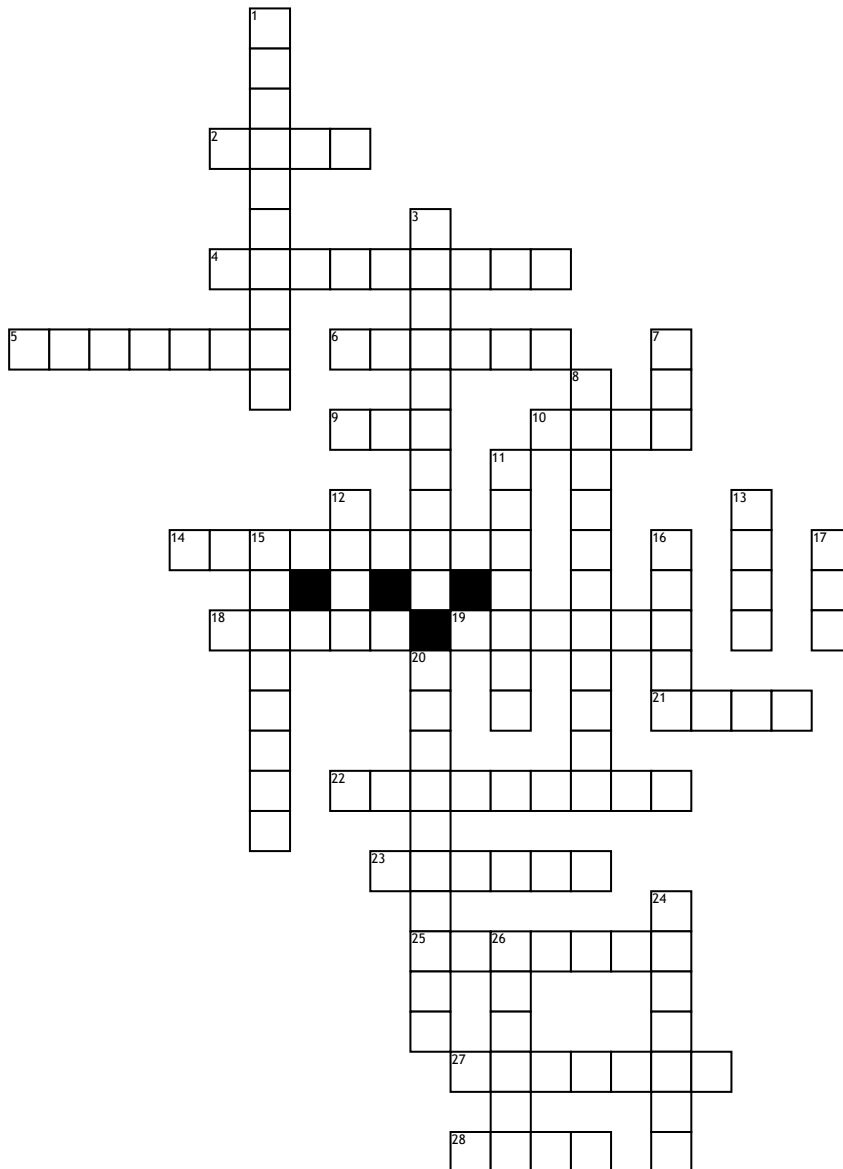


Name: _____

Date: _____

Dental anatomy



Across

2. the only non-calcified tooth tissue type
4. lobular extensions on the incisal edge of incisors
5. deep groove found on premolars and molars
6. surface of tooth closest to the midline
9. a circular depression commonly seen in posterior teeth
10. one of the primary anatomical division of a crown
14. when maxillary and mandibular teeth come in contact
18. when a child gets their first teeth they?
19. surface of tooth furthest from midline

21. part of tooth usually hidden by bone and/or tissue
22. characteristic differentiating teeth in the same class (2)
23. linear depression
25. first class of tooth to erupt
27. surface of tooth adjacent to the tongue
28. invagination of an amelodontal structure within the pulp known as ? in dente

Down

1. when two roots are separated
3. common characteristic of a group of similar teeth
7. tooth that is often referred to as part of the face
8. where adjacent teeth touch each other (2)

11. tissue found at the cervical area of teeth
12. the tip or peak of the root
13. anterior-posterior curve on the occlusal surface
15. slightly constricted tooth part, between crown and root
16. class of tooth always has more than one root
17. the upper and lower bony structure creating framework for the mouth
20. cusps that maintain vertical dimension
24. first set of teeth
26. dog like tooth