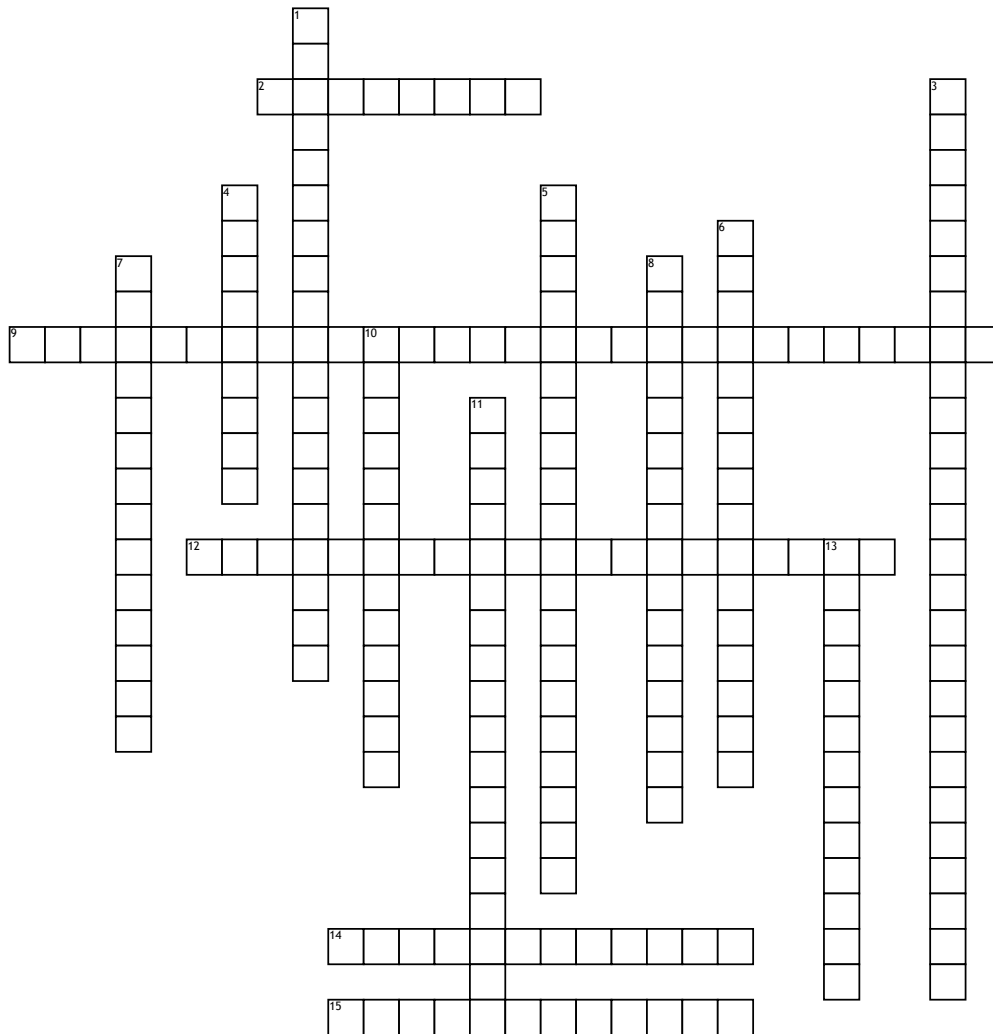


Name: _____

Date: _____

Injuries to the Arm, Wrist, and Hand (Part 2)



Across

2. Herniation of the synovium surrounding a tendon and subsequent filling of the area with synovial fluid, resulting in a visible bump seen through the skin.

9. The joint formed by the articulation between the proximal and intermediate phalanges of the digits (hinge type joint)

12. Buttonhole deformity whereby the proximal interphalangeal joint of the finger is forced through the central band of the tendon of the extensor digitorum muscle.

14. Anatomic region of the wrist where the median nerve and the majority of the tendons of the forearm pass into the hand.

15. Deformity of the distal interphalangeal joint of the finger caused by an avulsion of the tendon of the extensor digitorum muscle from the distal phalanx.

Down

1. An injury resulting in both the fracture of a bone and dislocation at the joint.

3. The joint formed by the articulation between the intermediate and distal phalanges of the digits (hinge type joint).

4. Anatomic name for the bones of both the fingers and/or toes.

5. A complex of symptoms resulting from pressure on the median nerve as it passes through the carpal tunnel of the wrist, causing soreness and numbness.

6. Sprain of the ulnar collateral ligament of the metacarpophalangeal joint of the thumb.

7. Fracture of the proximal fourth and/or fifth metacarpal bones.

8. Fracture and/or dislocation of the first metacarpal bone away from the greater multangular bone of the wrist.

10. Inflammation of the sheath of a tendon.

11. Inflammation of sheaths surrounding the extensor tendons of the thumb.

13. Anatomic region formed by the hook of the hamate bone and the pisiform bone, whereby the ulnar nerve passes into the hand.

Word Bank

phalanges

tenosynovitis

proximal interphalangeal joint.

de Quervain's disease

tunnel of Guyon

mallet finger

Bennett's fracture

distal interphalangeal joint

carpal tunnel syndrome

boxer's fracture

carpal tunnel

gamekeeper's thumb

fracture-dislocation

ganglion

boutonniere deformity