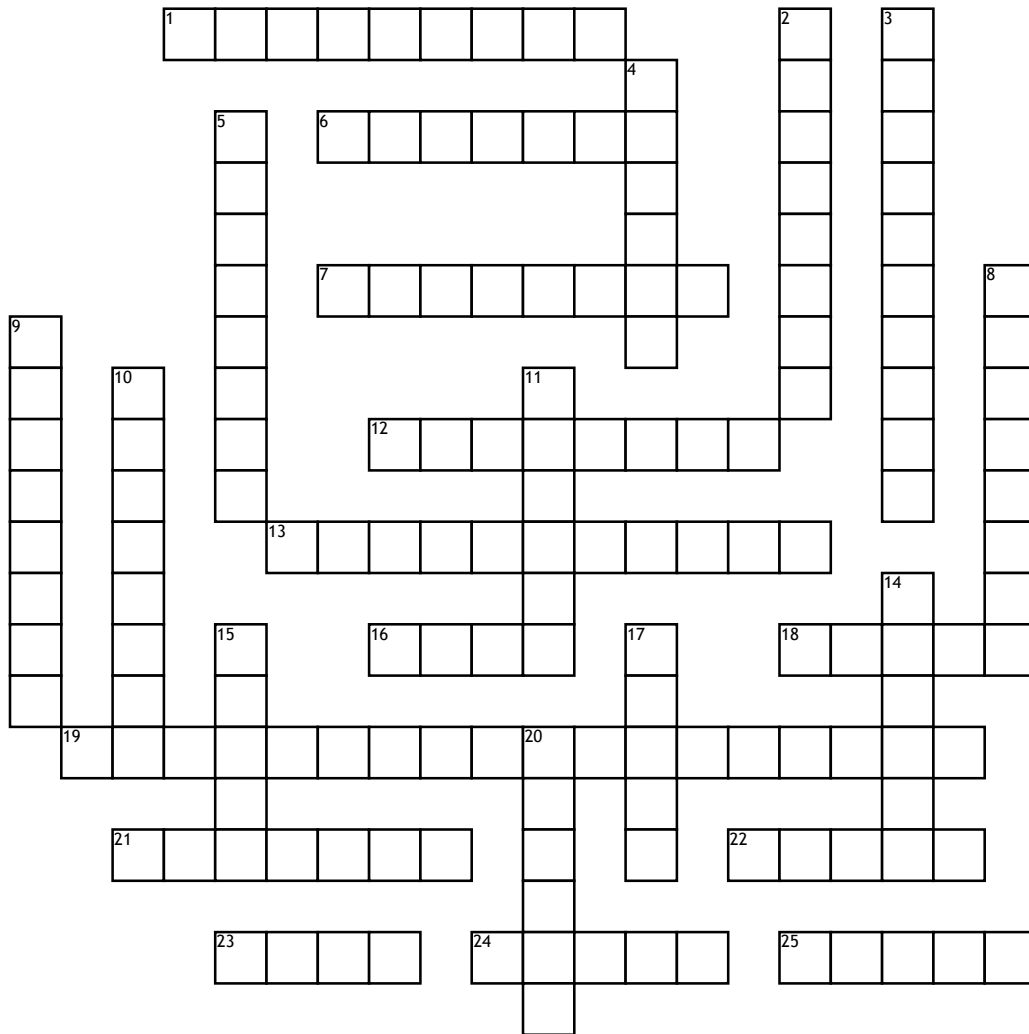


Medical Terminology: Integumentary system 4/5 B



Across

1. Thickened areas of epidermis.
6. A linear crack in the skin.
7. a scar resulting from formation and contraction of fibrous tissue in a wound.
12. Highly contagious, bacterial skin inflammation marked by pustules that rupture and become crusted.
13. A scratch or mark.
16. Is the hard protein substance found in the basal layer of the.
18. A thin flake of exfoliated epidermis.
19. Sexually transmitted, ulcer like lesions of the genital and anorectal skin and mucosa.

21. Localized collection of pus in a cavity formed by the inflammation of surrounding tissues.
22. An open sore on the skin or mucous membrane that can bleed and scar.
23. A skin condition that occurs when hair follicles plug with oil and dead skin cells.
24. The pigment called melanin is found in the basal layer of the epi-dermis. The combining form melan/o means?
25. A solid mass larger than 1-2 cm

Down

2. Epidermis are aptly called _____ cells.
3. Inflammation of the skin characterized by erythema, pruritus and various lesions.
4. An abnormal overgrowth of scar tissue that is thick and irregular.

5. A hereditary condition characterized by a partial or total lack of melanin pigment.
8. A painful nodule formed in the skin by inflammation originating in a hair follicle.
9. Reddish-brown, minute hemorrhagic spot of the skin that indicate a bleeding tendency.
10. An eating sore. Death of tissue associated with a loss of blood supply.
11. An area of pathologically altered tissue.
14. A flat, discolored spot on the skin up to 1 cm across.
15. A chronic autoimmune disease chart by inflammation of various parts of the body.
17. An area localized skin edema.
20. A solid mass on the skin up to 0.5 cm in diameter.

Word Bank

Albinism	Fissure	Acne	Furuncle	Abscess
Impetigo	Excoriation	Petechia	Lesion	Wheal
Lupus	Tumor	Keratosis	Scale	Ulcer
Black	Cicatrix	Herpes simplex virus	Macule	Keloid
Gangrene	Skin	Squamous	Papule	Dermatitis