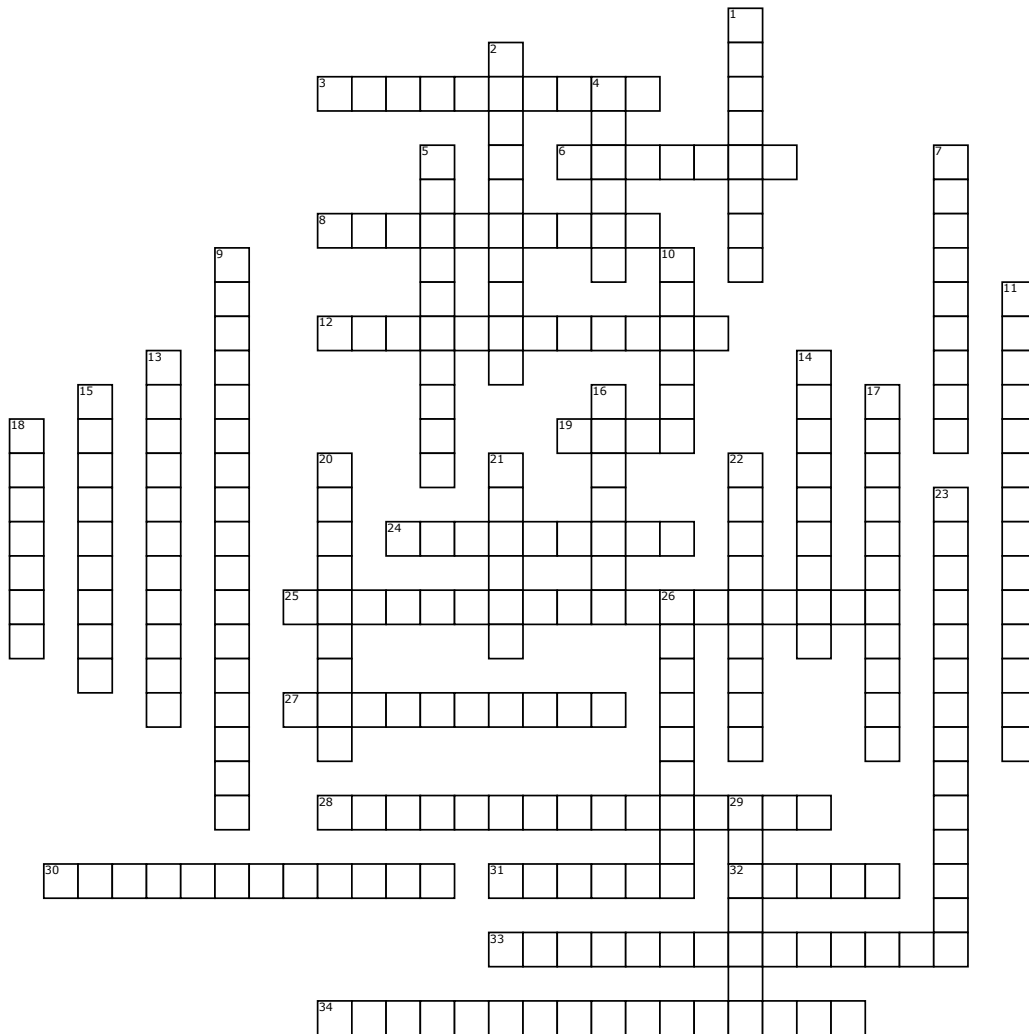


Ophthalmology Glossary Crossword Part Four



Across

3. A bulging defect of the cornea or sclera which is lined with uveal tissue
6. Ligaments that stretch from the ciliary processes to the lens that keep the lens in position
8. Inflammation of the optic disc
12. A shrunken globe
19. The vascular coat of the eyeball
24. Measurement of the intraocular pressure
25. Attachment of the iris to the lens capsule
27. Suturing the eyelids together
28. Inflammation of the whole eyeball
30. Adhesion of the conjunctiva to itself or to the cornea
31. Chronic superficial keratitis
32. The hole in the center of the iris

33. An abnormally small eyeball

34. The space filled with aqueous between the posterior aspect of the iris and the anterior aspect of the lens

Down

1. The transparent mass of gelatinous material filling the eyeball behind the lens
2. Night blindness
4. A constricted pupil
5. Hair growing from normally placed follicles causing irritation
7. A dilated pupil
9. The separation of the sensory retina from the retinal pigmentary epithelium
10. A slight haziness of the cornea
11. A small opacity on the posterior lens capsule, marking the site of previous hyaloid artery attachment

13. Abnormal light sensitivity

14. The process of liquifaction of the vitreous

15. Prolapse of the eyeball

16. Inflammation of the uvea

17. Oedema of the optic disc

18. A blind spot in the visual field

20. Sebaceous gland in the tarsal plate

21. Drooping of the upper eyelid

22. More than one pupil

23. Abnormal vascularization of the iris, associated with uveitis

26. An involuntary rapid movement of the eyeball

29. A fluorescent layer in the choroids in the dorsal fundus

Word Bank

Miosis
Polycoria
Microphthalmos
Nystagmus
Staphyloma
Mittendorf's dot
Syneresis

Papillitis
Retinal detachment
Posterior chamber
Zonules
Ptosis
Posterior synechiae
Uvea

Uveitis
Trichiasis
Proptosis
Vitreous
Nebula
Pupil
Nyctalopia

Scotoma
Pthisis bulbi
Panophthalmitis
Tapetum
Meibomian
Tarsoraphy
Papilledema

Rubeosis iridis
Pannus
Tonometry
Photophobia
Symblepharon
Mydriasis