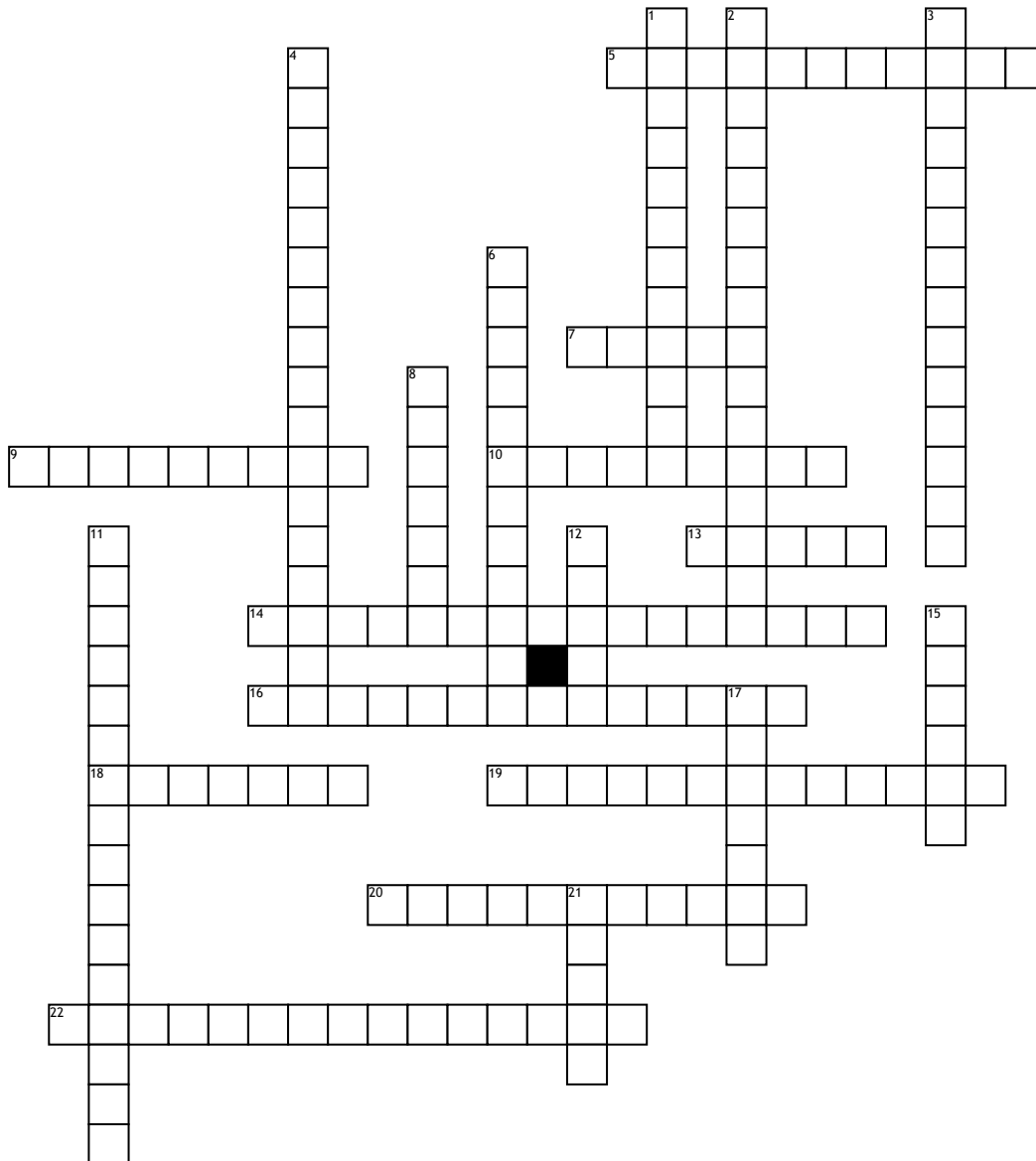


Pelvic Girdle and Lower Limbs



Across

5. group of five long bones in the foot. located between the tarsal bones of the foot

7. larger of the two bones in the lower leg. located on the shin

9. bones that make up the toes of the foot, located above the metatarsals

10. large bone that forms the foundation of the rear part of the foot. located on the heel of the foot

13. often a site of lower back problems and is the uppermost and largest part of the hipbone. Located on the hipbone

14. elevation on the proximal and anterior aspect of the tibia. located below the anterior surfaces of the lateral and medial tibial condyles end

16. anterior boundary of the perineum and is located on the anterior side of the pelvis

18. small bones that support a certain part of the foot and include bones of the ankle and heel. located between the metatarsus and the leg

19. larger than the lateral condyle due to more weight bearing. located on the upper extremity of the tibia.

20. is the proximal portion of the femur and is supported by the femoral neck. Located on the upper extremity of right femur

22. bony bump on the inner side of the ankle also the end of the shinbone. located below the tibia

Down

1. irregular quadrant form and presenting above a flattened articular surface. located on the outer sides of the knee

2. part of the fibula and one out of two bones of the lower leg. located on the outside of the ankle joint

3. one of the two projections on the lower extremity of the femur and more prominent. Located under the articular cartilage

4. a rounded bone that extends from the ischium. Located just below the ischial spine

6. small, oval-shaped dimple on the ball-shaped end on top of the femur. Located on the thighbone

8. flat, rounded triangular bone which articulates with the femur. Located in front of the knee joint

11. large aperture situated between the ischium and pubis. located in the hipbone

12. a pair of bones forming the two sides of the pelvis. Located in front of the pelvic girdle

15. leg bone on the lateral side of the tibia and most slender of all the long bones. located within the lateral aspect of the leg

17. the lesser sciatic notch allows the passage of nerves and blood vessels to and from the leg. located below the ilium and behind the pubis

21. only bone in the thigh and the longest bone in the body. can act as the site of origin and attachment of many muscles and ligaments. Located at the thighbone