

Name: _____

Date: _____

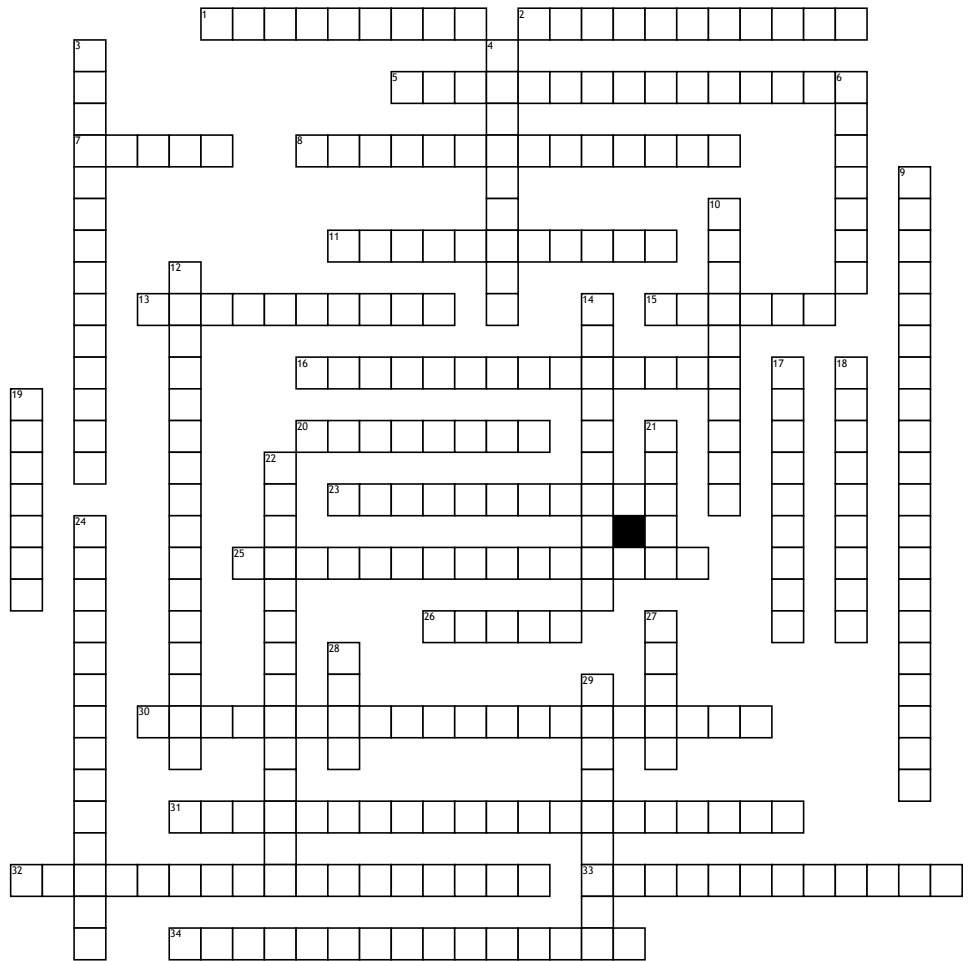
Renal and GU Seminar

Across

1. this is a common means of providing vascular access in patients requiring hemodialysis (2 wrds)
2. this syndrome may affect the lungs and kidneys
5. this class of antibiotics is a common cause of ATN/AKI in hospitalized patients
7. Most common cause of acute cystitis (2wrds, first word only first letter used)
8. risk factor for development of testicular cancer
11. This reflex is absent in testicular torsion
13. imaging of choice in testicular torsion; may be done bedside
15. Age, weight, and _____ may affect GFR estimation
16. Commonly used medication in treatment of UTI but may be linked with pulmonary fibrosis especially in elderly patients
20. Inability to retract the foreskin
23. Tx for gonorrhea is _____ IM and oral doxycycline
25. this may be given to reduce the incidence of contrast related nephropathy
26. this type of malignant tumor often presents as a palpable, asymptomatic abdominal mass in children
30. most common cause of nephrotic syndrome in children (3 wrds)
31. most common cause of intrinsic renal failure in hospitalized patients; aka. AKI (3 wrds)
32. Most common inheritance pattern in polycystic kidney disease (2 wrds)
33. most common histological type of bladder cancer; _____ cell
34. may be beneficial in treatment of interstitial nephritis (medication class)

Down

3. along with 3+ proteinuria, this may also be present in nephrotic syndrome



4. This type of renal failure should be suspected if casts and proteinuria are present on UA
6. Biggest, modifiable risk factor in development of bladder cancer
9. chronic pain condition that causes pain with bladder filling and is more common in women (2 wrds)
10. renal and GU god!!!!!!!
12. One of several tumor markers used in testicular cancer; may also be used to screen for congenital abnormalities in pregnancy
14. abnormal protein associated with multiple myeloma that is nephrotoxic
17. Most common (and often only) presenting symptom in bladder cancer
18. most common histological type of renal cancer (2 wrds)

19. most common type of kidney stones (may be oxalate or phosphate)
21. This PE maneuver involves elevating the testes which alleviates pain in epididymitis
22. Characterized by podocyte damage, this should be suspected in an adult heroin user presenting with nephrotic syndrome (first two words only)
24. this cause of ATN is also referred to as Berger disease
27. these exercises may be beneficial in stress incontinence
28. In postinfectious glomerulonephritis, the urine is often described as _____ colored; also a soft drink
29. type of cast that may be seen in ATN