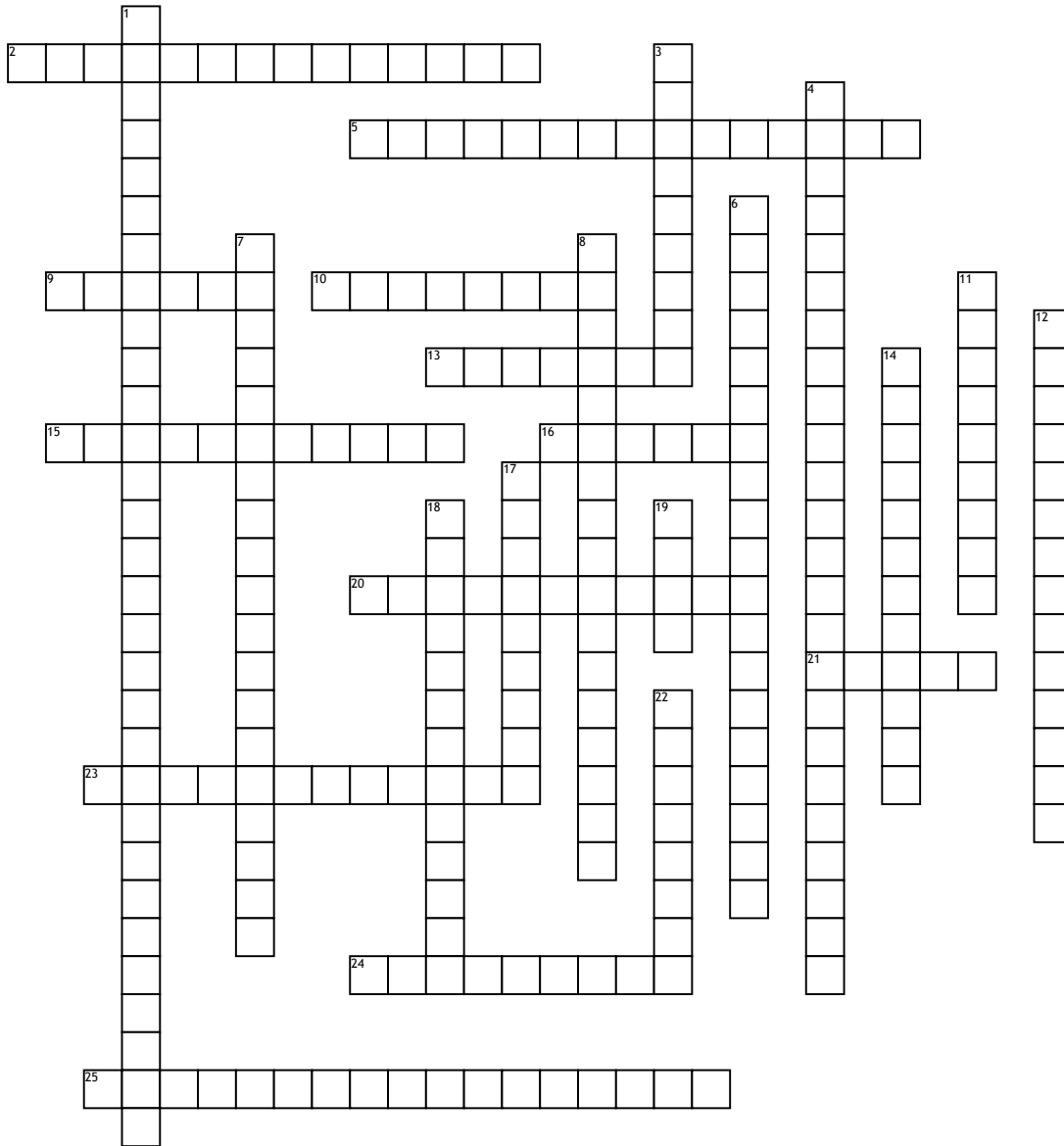


Skeletal System 6



Across

- 2. proximal to the ulna
- 5. posterior of the ulna
- 9. made up of two irregular rows of four bones each
- 10. distal of the humerus
- 13. the sit down bone
- 15. palm of the hands
- 16. lateral bone on the thumb side
- 20. total of eight bones (hand)
- 21. connects posteriorly w/ the sacum @ the sacroiliac joint
- 23. formed by two coxal bone or hip bone

- 24. bones of the fingers

- 25. both proximal and distal end of the radius

Down

- 1. iliac crest ends anteriorly/posteriorly
- 3. articulates bones of the forearms; lateral ball-like
- 4. allow corresponding process of the ulna move freely when the elbow is bent or extended
- 6. radioulnar joints conneted by this

- 7. a roughened area that receives body weight when you are sitting

- 8. tendon of the bicep muscle attaches

- 11. part of the hip bone

- 12. posterior surface of the radical glove

- 14. runs oblique down the posterior aspect of the shaft

- 17. part if the hip bone

- 18. depression of the anterior trochlea

- 19. medial of the forearms

- 22. two bones; radius and the ulna