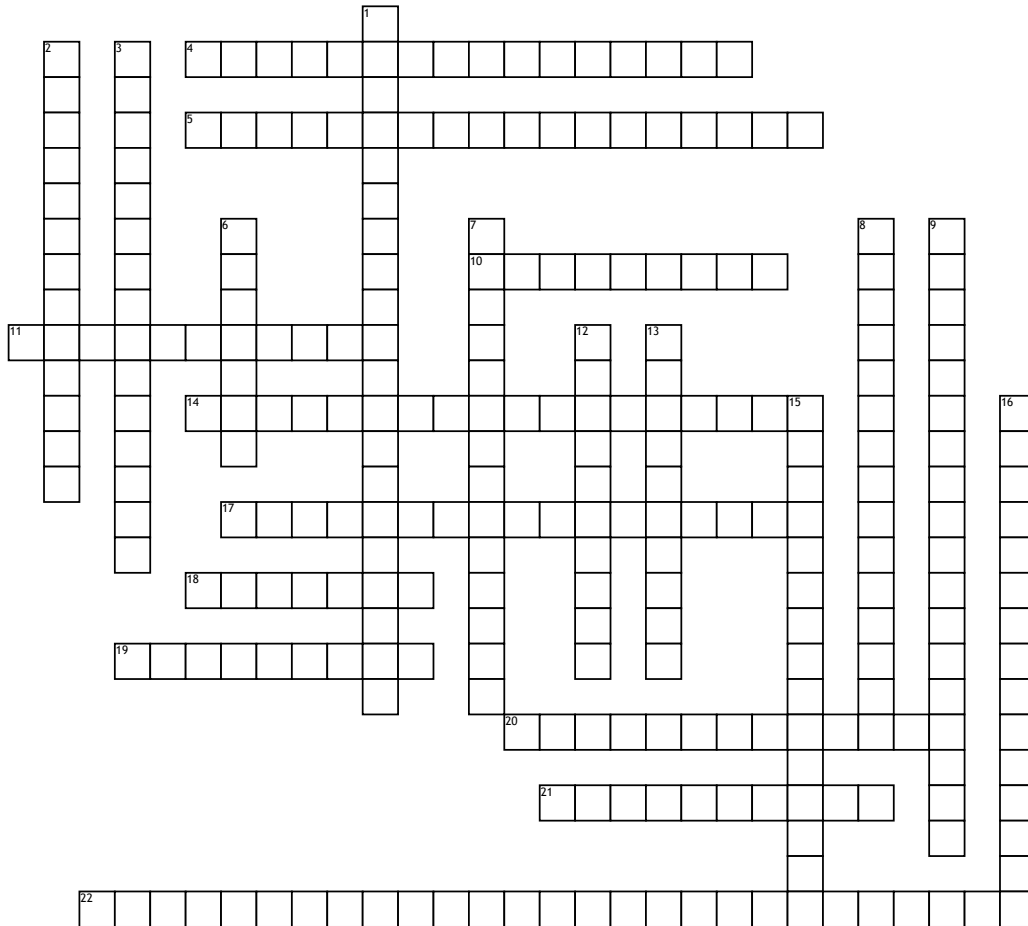


# Upper Arm and Posterior Forearm



## Across

4. most medial anterior muscle of the upper arm  
 5. Abductor pollicis longus, extensor pollicis brevis and extensor pollicis longus make up what?  
 10. the dorsal scapular nerve innervates what muscles?  
 11. innervates the posterior side of the arm  
 14. innervates the supraspinatus and infraspinatus  
 17. innervates serratus anterior  
 18. Elevates the ribs and originates at C3-6

19. located deep to the aconeus and supinates the forearm  
 20. innervates the deltoid and teres minor  
 21. provides ligamentous action at the sternoclavicular joint  
 22. inserts at the 2nd metacarpal

6. originates on the lateral epicondyle of the humerus and causes elbow extension  
 7. Muscle consisting of 3 heads located on the posterior upper arm  
 8. Inserts at the intertubercular surface of the humerus  
 9. Another name for the middle subscapular nerve  
 12. causes elbow flexion and is located deep to the biceps brachii  
 13. innervates 2 forearm flexors  
 15. inserts at the extensor hood of the index finger  
 16. inserts on the lateral aspect of the styloid process of the radius

## Word Bank

- |                      |                                |                  |                     |
|----------------------|--------------------------------|------------------|---------------------|
| Coracobrachialis     | extensor carpi radialis longus | ulnar nerve      | Scalene             |
| Pectoralis minor     | radial nerve                   | triceps brachii  | Brachialis          |
| anatomical snuff box | Subclavius                     | Pectoralis Major | suprascapular nerve |
| supinator            | axillary nerve                 | rhomboids        | extensor indicis    |
| aconeus              | long thoracic nerve            | brachioradialis  | Biceps Brachii      |
| thoracodorsal nerve  | common extensor tendon         |                  |                     |